Lateral Window Sinus Lift by the Double Window Technique With the Utilization of PRF - A Case Report

Presenter: Yu Kubota DDS, PGY3 in Periodontics Department, Indiana University, Halide Namli Kilic DDS, PhD, MSD

Academy of Osseointegration

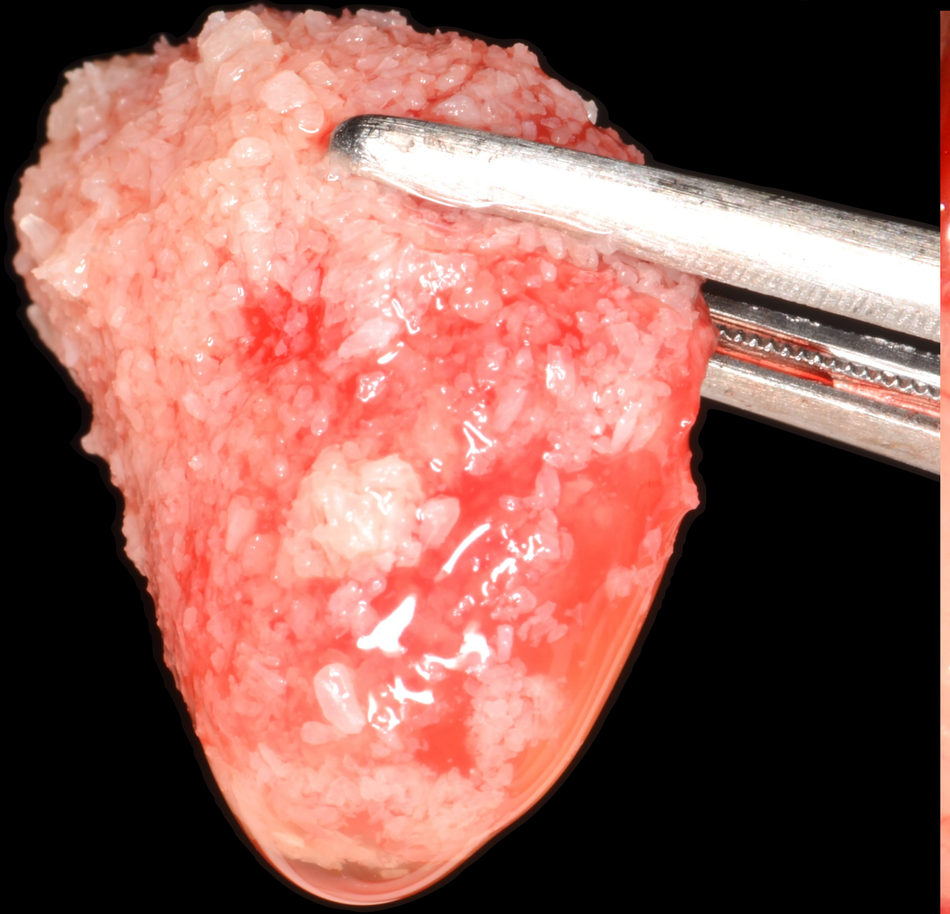

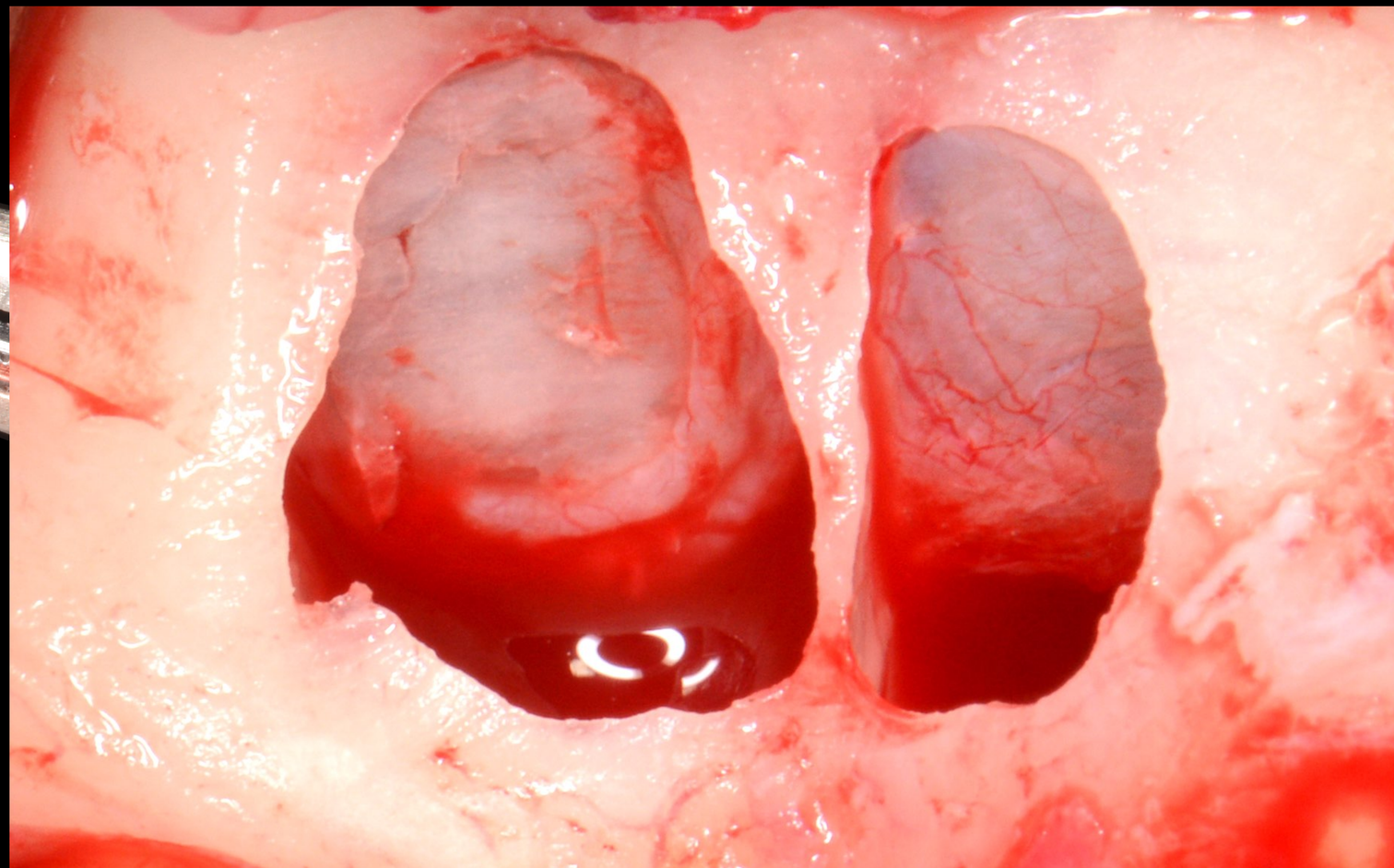

Introduction:

Anatomical limitations at the implant position (#3):

- **Insufficient bone height/width: 1mm residual bone**
- **Presence of septa: 5.7 mm high**
- **Soft tissue limitations**

Case Presentation:

42 years old, healthy female patient

Anatomical limitations at the implant position

Planned **Double Window Lateral Sinus Lift** to avoid the septum

- Carefully elevating Schneiderian Membrane
- **Valsalva maneuver**: Confirmed membrane integrity
- Sinus filled with **sticky bone** (Xenograft, Allograft, and **i-PRF**)
- Windows covered with collagen and **A-PRF membrane**
- Sutured without tension

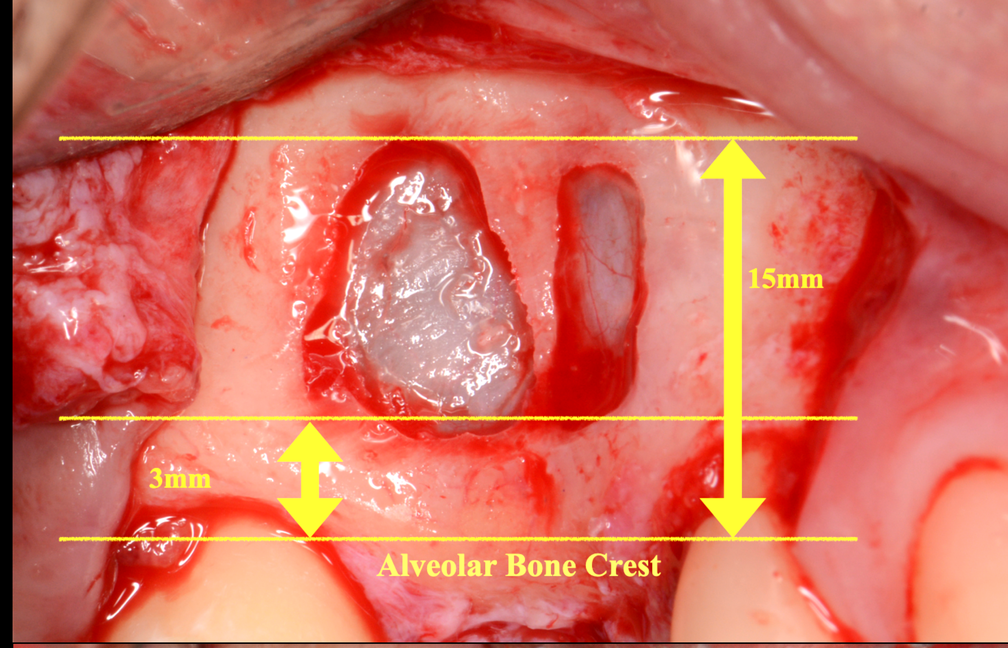

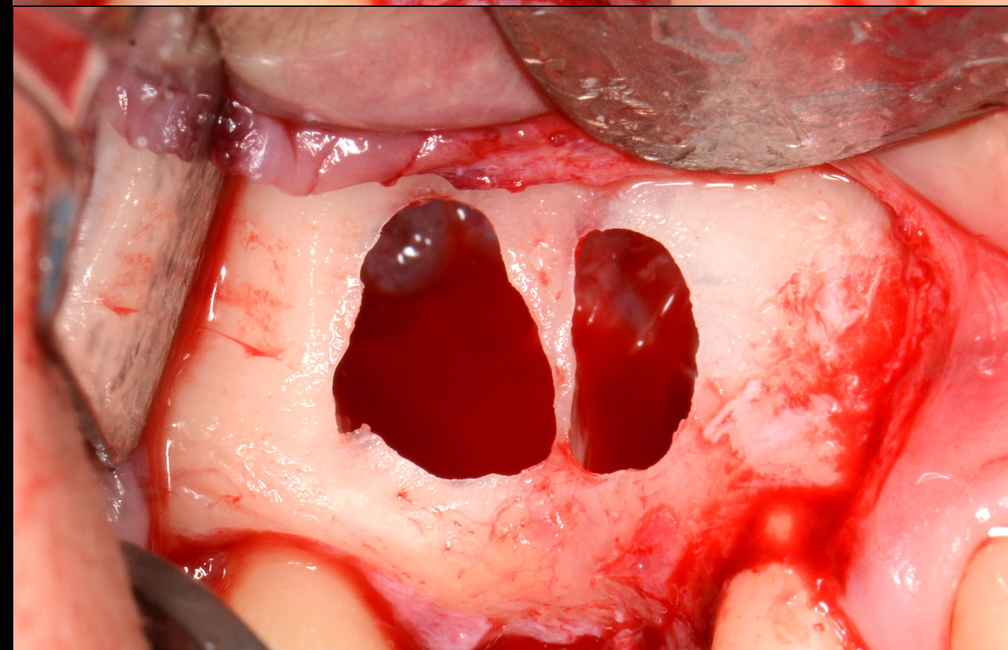

Valsalva Maneuver to confirm membrane integrity

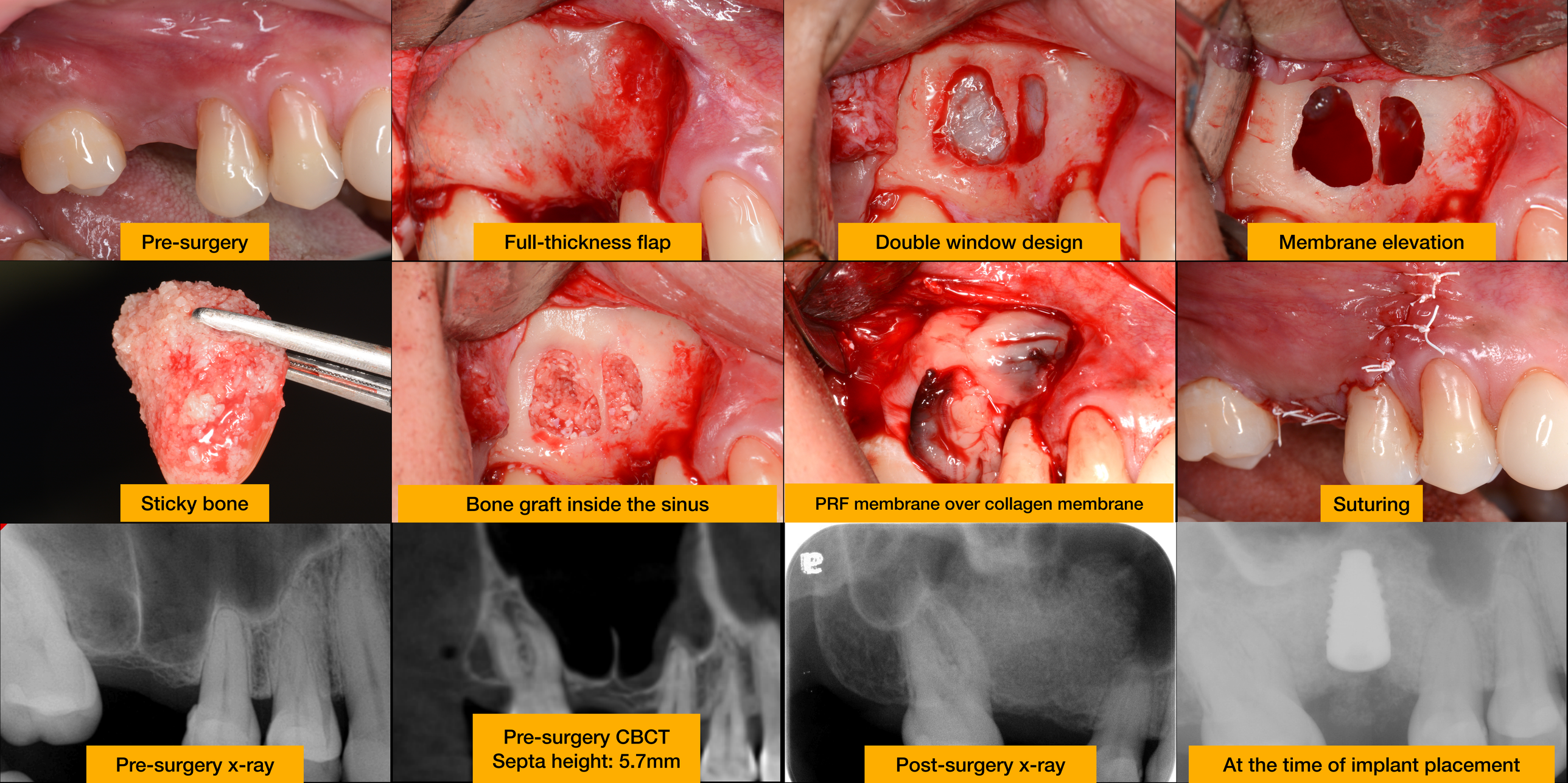
Pre-surgery
Full-thickness flap
Double window design
Membrane elevation
Sticky bone
Bone graft inside the sinus
PRF membrane over collagen membrane
Suturing
Pre-surgery x-ray
Pre-surgery CBCT
Septa height: 5.7mm
Post-surgery x-ray
At the time of implant placement

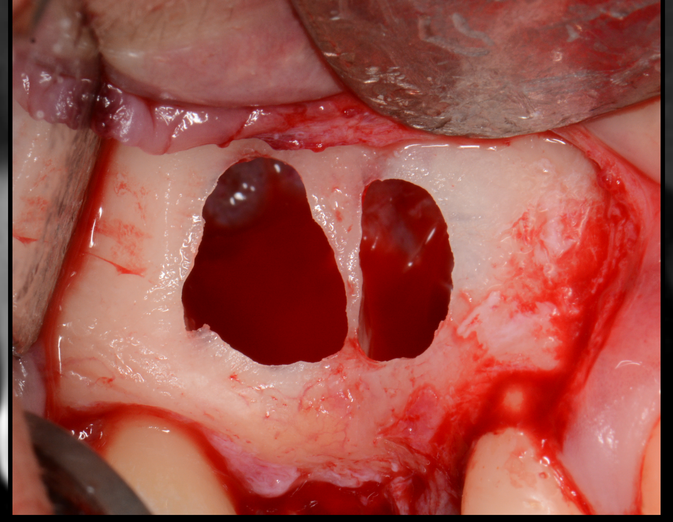
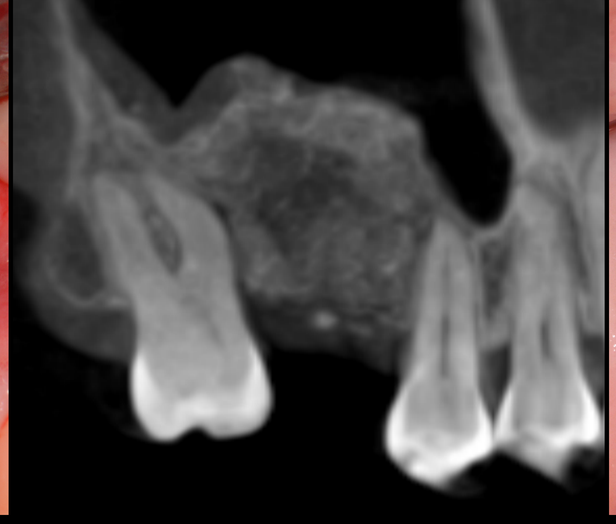
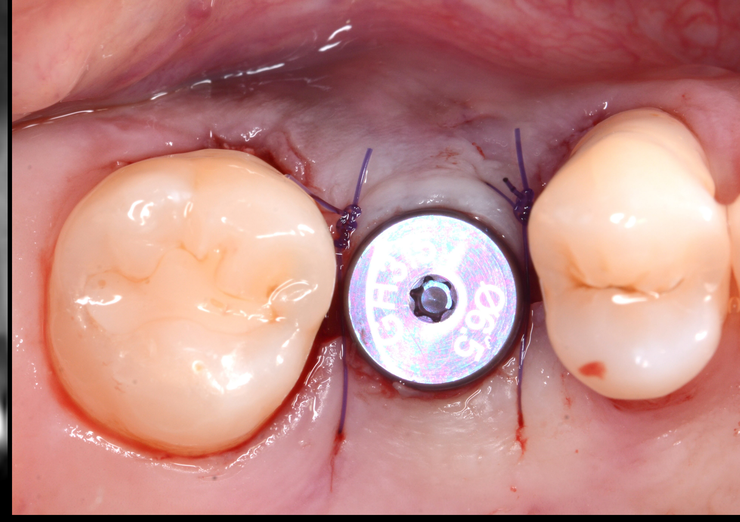

Result:

- Achieved to **gain 14mm bone height** after the procedure
- Achieved to place an implant with primary stability on #3 site

Conclusion:

- Double Window Design

- **Successfully avoided sinus septa and lifted sinus membrane without perforation**

- Platelet-Rich Fibrin (PRF)

- **Enhanced graft cohesion**
- **Accelerated soft tissue healing and reduced patient discomfort**