Photobiomodulation Therapy for Complete Mandibular Paresthesia Following Vestibuloplasty With Free Gingival Graft

Sara Khraibut, DDS, A. Ghassemi, DDS, MS, J. Golob Deeb, DDS, MS

Academy of Osseointegration

VCU Virginia Commonwealth University

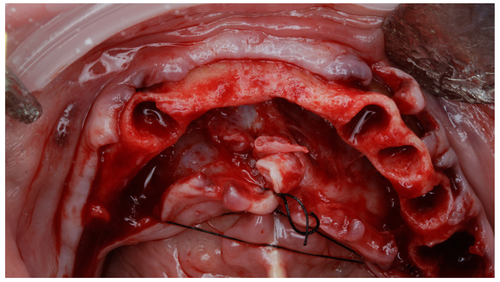
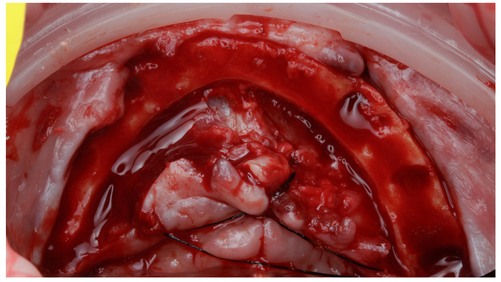
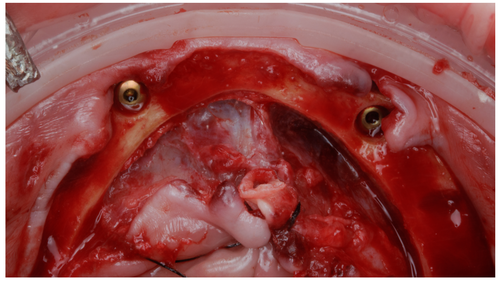
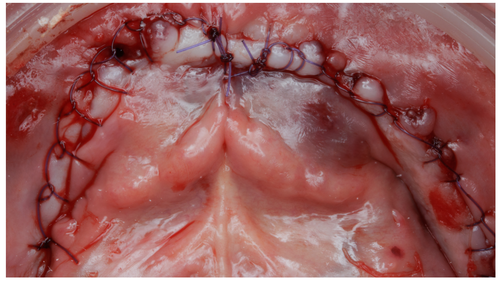

2 week post-op (PO)

Introduction:

After mandibular extractions, alveoloplasty, and immediate implant placement for an overdenture, the patient presented with complete loss of vestibular depth and keratinized tissue in the anterior mandible—compromising hygiene, prosthetic stability, and peri-implant health. Vestibuloplasty with a free gingival graft was planned to restore vestibular depth and improve the peri-implant mucosal phenotype. Preoperative CBCT imaging confirmed that the bilateral mental foramina were in close proximity to the alveolar crest which is increased the risk of neurosensory disturbance.

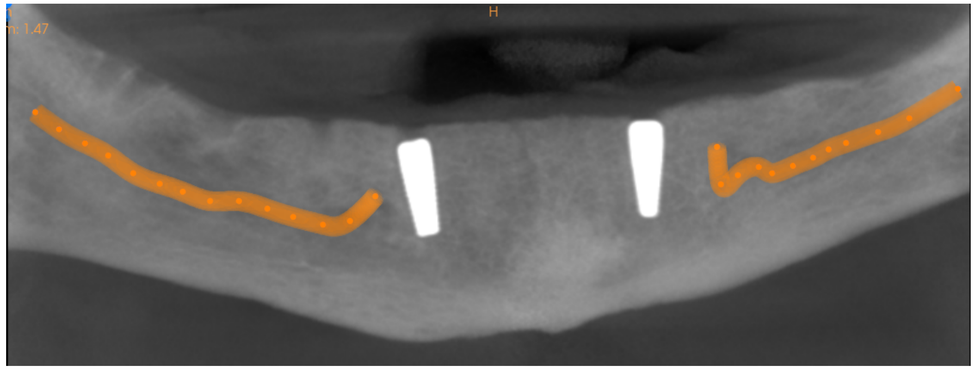

Immediate CBCT

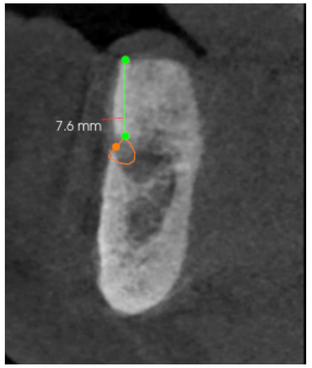

Distance from IAN - right side

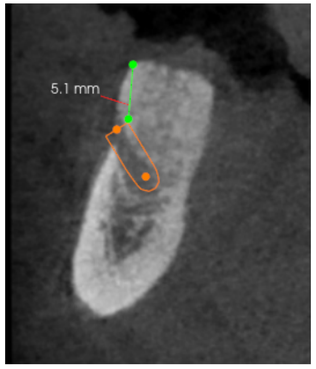

Distance from IAN - left side

Photobiomodulation Therapy for Complete Mandibular Paresthesia Following Vestibuloplasty With Free Gingival Graft

Sara Khraibut, DDS, A. Ghassemi, DDS, MS, J. Golob Deeb, DDS, MS

Academy of Osseointegration

VCU Virginia Commonwealth University

Methods:

Despite careful blunt dissection to avoid injury to mental nerve, patient reported complete paresthesia on both sides of the mental nerve area (chin and lower lip) two weeks postoperatively. To enhance the neurosensory recovery, photobiomodulation (PBM) therapy was initiated, targeting intraoral surgical areas, adjacent extraoral zones, and regional lymph nodes. Two PBM sessions within one week were performed using Nd:YAG laser (Fotona), 1064 nm wavelength using Genoa handpiece with 1 cm diameter at 0.5 W 60 seconds per site.

PBM settings

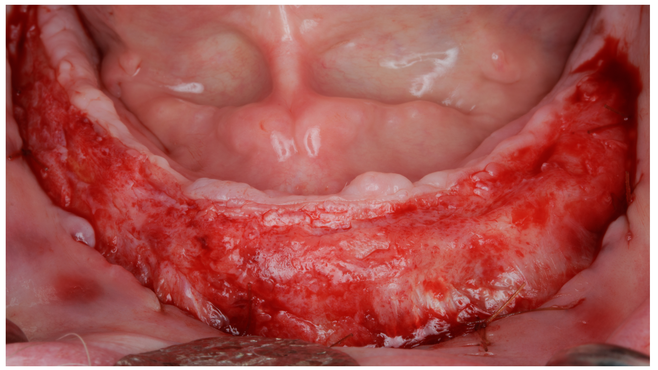

Periosteal bed

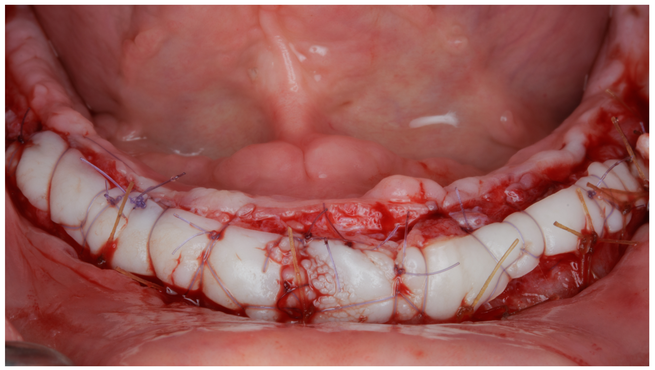

Free gingival graft at immediate PO

Nerve mapping at 2 week PO

Photobiomodulation Therapy for Complete Mandibular Paresthesia Following Vestibuloplasty With Free Gingival Graft

Sara Khraibut, DDS, A. Ghassemi, DDS, MS, J. Golob Deeb, DDS, MS

6-week PO nerve mapping

6 week PO intra-oral presentation

Results:

After two PBM sessions, the patient reported marked improvement in neurosensory function, with over 90% resolution of paresthesia and only minor residual hypoesthesia. Subjective quality of life, assessed through self-report, improved significantly, with restoration of lower facial sensation, improved speech confidence, and reduction in anxiety related to the neuropathy. No further interventions were required. The vestibular depth and keratinized tissue remained stable throughout healing.

Conclusion:

This case highlighted the role of photobiomodulation as a non-invasive, adjunctive therapy in accelerating peripheral nerve recovery following oral surgical procedures. PBM has been shown to enhance neural regeneration by stimulating mitochondrial activity, reducing inflammation, and promoting axonal growth. Evidence supports its efficacy in reducing the duration and severity of postoperative paresthesia, especially when applied early. Incorporating PBM into the postoperative management protocol may significantly improve patient outcomes in cases with high neurosensory risk.

2-week PO following uncovery